



## Original Article



# The Effect of Topical Nitroglycerin on Wound Healing in Rabbits using Histopathological Investigation

Arman Moshaveri<sup>1,\*</sup> , Daryoush Babazadeh<sup>2</sup> , Faezeh Modarresi-Ghazani<sup>3</sup> , Veghar Hejazi<sup>4</sup> , Muhammad Saeed<sup>5</sup> , and Pouria Ahmadi Simab<sup>6</sup>

<sup>1</sup> Faculty of Veterinary Medicine, Karaj Branch, Islamic Azad University, Karaj, Iran

<sup>2</sup> School of Veterinary Medicine, Shiraz University, Shiraz, Iran

<sup>3</sup> Drug Applied Research Center, Tabriz University of Medical Sciences, Tabriz, Iran

<sup>4</sup> MD, Tabriz University of Medical Sciences, Tabriz, Iran

<sup>5</sup> College of Animal Science and Technology, NW A&F University, Yangling, Shaanxi, China

<sup>6</sup> Faculty of Veterinary Medicine, Sanandaj Branch, Islamic Azad University, Sanandaj, Iran

\* **Corresponding author:** Arman Moshaveri, Faculty of Veterinary Medicine, Karaj Branch, Islamic Azad University, Karaj, Iran. Email: [armanvetmoshaveri@gmail.com](mailto:armanvetmoshaveri@gmail.com)

### ARTICLE INFO

#### Article History:

Received: 25/10/2021

Accepted: 10/02/2022



#### Keywords:

Histopathology

Nitroglycerin

Rabbit

Wound Healing

### ABSTRACT

**Introduction:** Nitroglycerin can increase the Cycle Guanosine Mono Phosphate level, enhance nitric oxide rate in tissues dilate vessels, and intensify perfusion within tissues. The aim of the present study was to conduct a microscopic investigation addressing the effect of topical 2% Nitroglycerin ointment on wound healing in rabbits.

**Materials and methods:** Six adult male New Zealand white rabbits, weighing approximately 2.25 kg were used. Two wounds were created on each side of the spinal column. The wounds reached the deep fascia and their dimensions were 15 × 15 mm. The left wound was used as the control and the right wound was used as the experimental one. Immediately after the creation of wounds, a layer of nitroglycerin 2% with 1 mm thickness was put on the experimental wound daily for seven days. On days 3, 5, 7, and 14 after cutting, both the experimental and control wounds with a margin of healthy tissues were taken for the histopathological examination.

**Results:** The distance of the two edges on the wound in treated wounds reached a significant difference, compared with control wounds on day 14. The number of inflammatory cells (with neutrophils format) in the treatment group was significantly less than those of the control group starting from day 5. In addition, the fibrin clot diameter in the treatment group was significantly less than the control group on days 5, 7, and 14. At the beginning of the experiment angiogenesis in the control group was more than in the treatment group, but it was the same in both groups on day 7, and angiogenesis in the treatment group was more than in the control group after day 7. The volume of granulation in the treatment group was more than control group and there was a significant difference on days 5, 7, and 14. Epithelial tissues diameter was higher in the treatment group and the difference became significant on day 14.

**Conclusion:** In conclusion, the findings indicated a promising function of topical NTG in wound healing of anal fissures, tendinopathies, CNH, diabetic foot, or skin flap necrosis.

## 1. Introduction

Wound healing stimulation is one of the proposed issues in medical and veterinary medicine. Different physical and chemical procedures have been proposed to heal the wound and which has been investigated and

regularly updated as an important issue. Perfusion is one of the most important factors in wound healing procedure, so the medicines which increase perfusion to the wound can have a positive effect on this procedure<sup>1,2</sup>.

Nitroglycerin (NTG) known as 1,2,3-trinitro propane is one of the medicines which enhances Nitric Oxide (NO) rate in tissues, dilates vessels, and intensifies perfusion within the tissues by an increase in the Cycle Guanosine Mono Phosphate (CGMP) level<sup>2,3</sup>. Topical NTG and lidocaine significantly increase radial artery diameter (RAD) within 30 to 60 minutes with no effect on the contralateral radial artery or blood pressure, indicating a direct local effect on the radial artery<sup>4</sup>. Moreover, this medicine prohibits calcium channels activities to change the calcium level intracellularly<sup>5</sup>.

A great deal of basic and clinical research on the physiologic and pathophysiologic roles of NO in cardiovascular function has been conducted since Endothelium-derived Relaxing Factor (EDRF) was found to be NO<sup>6</sup>. Furthermore, intracellular calcium ion has an important role on the overall process of wound healing. These findings were applied in previous studies to indicate the role of calcium in human wound healing<sup>5</sup>.

Topical nitroglycerin ointment (NTGO) would be absorbed through the skin and complete its effectiveness which lasts for 2-12 hours. NTC has a very short half-life (1-4 min in humans) and it would be metabolized in the liver<sup>7</sup>.

Some limited investigations have been conducted on the topical effects of NTG on the healing of anal fissures and the success rate of skin graft which led to contradicted results<sup>8,9</sup>. The effect of honey and NTG on wound healing was investigated<sup>10</sup>. The findings revealed that the wound healing period in honey and NTG groups was significantly shorter than the control group, and also, NTG could increase the blood flow of the wound site, and consequently accelerated the healing process; however, it took some time for its effects to appear. Hegggers et al.<sup>11</sup> compared the effect of Aloe Vera and NTG on wound healing and found that Aloe Vera was more effective. The effects of Sildenafil and NTG on skin flaps of rats after nicotine application were investigated, the results indicated that cotreatment with oral sildenafil and local NTG can improve skin survival<sup>12</sup>. In another study, Dunn and Brodland<sup>13</sup> examined the effect of this medicine on 88 patients with surgical wounds but no significant effects on skin graft and flap enhancement were reported. On the other hand, during an investigation on rats' intestinal anastomotic healing<sup>14</sup>, it was mentioned that NTC was an effective medicine. Furthermore, in a study by Hwang et al.<sup>15</sup> the positive effects of NTG on hemorrhoidectomy and wound healing were confirmed. In an investigation Sanei et al.<sup>9</sup>, they compared glyceryl trinitrate (GTN) with diltiazem for the treatment of chronic anal fissure and it was concluded that both were equally effective and might be preferred to become the first line in treating chronic anal fissures. Kim et al.<sup>16</sup> evaluated the efficacy of combining NTGO and Adipose-Derived Stem Cells (ADSCs) as a superior wound healing treatment and reported that wound-healing rate was accelerated in the NTGO-applied wound. Karanik et al.<sup>17</sup> also assessed the effects of GTN on promoting wound healing after hemorrhoidectomy and the findings were indicative of the GTN effectiveness in the treatment within three postoperative weeks.

The meta-analysis of NTGO use after hemorrhoidectomy as an analgesic and wound healing accelerator has been focused in a study<sup>18</sup>. It was reported that GTN had a significant pain-relieving effect lasting three to seven days postoperatively and significantly improved wound healing at three weeks. The aim of the current study was to investigate the histopathological effects of NTG 2% on wound healing of rabbit skin.

## 2. Materials and Methods

### 2.1. Animals

Six male adult New Zealand white rabbits aged 8-9 months, weighing approximately 2 kg were included in this study. The rabbits were kept in individual cages with equal environmental conditions and diet. They had 12 hours of light and 12 hours of darkness, also the temperature and humidity were kept at  $22 \pm 2^\circ\text{C}$  and  $50 \pm 5\%$  respectively. The rabbits were fed standard food pellets (Razi institute, Iran) starting two weeks before the investigation.

### 2.2. Wound cutting method

Two wounds were created on each side of the spinal column of all animals. The wounds reached to the deep fascia and their dimensions were  $15 \times 15$  mm. The left wounds were used as control and the right wounds as the experimental wounds.

### 2.3. Nitroglycerin application

Immediately after cutting the wounds a layer of NTG 2% (Berenguer-Infale, Germany) in vaseline (Tehran Chemi Company, Iran) base with 1 mm thickness was used on the experimental wounds daily for seven days, the control wounds received a layer of vaseline with the same thickness.

### 2.4. Histopathological investigation

On days 3, 5, 7, 14, 21, 28 after cutting, 10 samples with a margin of healthy tissues from both experimental and control wounds of a rabbit on each day of sampling were taken for histopathological examination. The samples were fixed in 10% neutral formalin solution and dehydrated with a series of ethanol solutions. The samples were also processed by the conventional paraffin embedding method. Microtome sections were prepared at  $5\mu$  thicknesses, stained with Hematoxylin and Eosin (H & E), and observed under a light microscope (Olympus, Japan). Histopathological assessments were made based on the observations, the distance between the wound edges measurement, infiltration rate of inflammatory cells, the diameter of a fibrin clot, the number of blood vessels, the volume of granulation, and the diameter of newly formed epithelial tissue.

### 2.5. Statistical analysis

The data recorded from both experimental and control

wounds were evaluated and analyzed by comparing the means in SPSS software (version 22). Duncan test was used to investigate the significant differences at level of  $p \leq 0.05$ .

### 3. Results and Discussion

In the current study, the effects of topical NTG on the process of wound healing were assessed using histopathological investigations. The results indicated that the distance of wound edges, an important indicator of wound healing, became significantly shorter 14 days after starting the treatment ( $p \leq 0.05$ , Table 1). This is important because the shorter the wound edges are, the sooner the wound will shrink and start healing. In addition, the infiltration of inflammatory cells significantly decreased from the fifth day ( $p \leq 0.05$ , Table 2). Comparing the microscopic images of control and treated wounds on the third day, it was obvious that the inflammatory cells decreased in the treated wound while there was an aggregation of these cells in the control wound (Figures 1 and 2). A lower infiltration of inflammatory cells is an indicator of faster inflammation clearance and consequently, faster healing. The histologic findings also reported that angiogenesis was at a similar level at the beginning of the treatment, while on the fifth day, there was severe angiogenesis in the control group and newly formed vessels in the treatment group (Figures 3 and 4).

This trend was reversed when the number of blood vessels formed in the treatment group started increasing until it reached a significant level on day 14 (Table 4). In fact, the medicine causes the blood vessels to become more stable until the complete treatment of the wound in the treatment group is achieved. The Higher vessel formation and its continuity until the end of the treatment improved the transfusion of healing factors and accelerated healing. As the treatment with topical NTG continued, a better organization of collagen and limitation of the wound was observed in the treatment group, compared to the control group (Figures 5 and 6). Fibrin clot average diameter was lower in the treatment group at the beginning of treatment and it reached a significant level on day 5 ( $p \leq 0.05$ ) and remained that way by the end of the experiment (Table 3). This means that there is a negative relationship between granulation and fibrin clot diameter, so the less the fibrin clot diameter, the more the granulation volume resulting in faster healing. Epithelial tissue formation had started on day 14 in the treatment group and day 21 in the control group, and it was higher in the treatment groups compared to the control group on days 14, 21, and 28 ( $p \leq 0.05$ , Table 6, Figures 7 and 8). The more the epithelial tissues cause faster wound healing with respect to the studies conducted on chronic fissure healing on 50 people. Newly formed granulation was additionally higher in the treatment group from the beginning of the experiment and significant from

**Table 1.** Mean standard deviation of the distance of wound edges in the skin of rabbits during four weeks of study

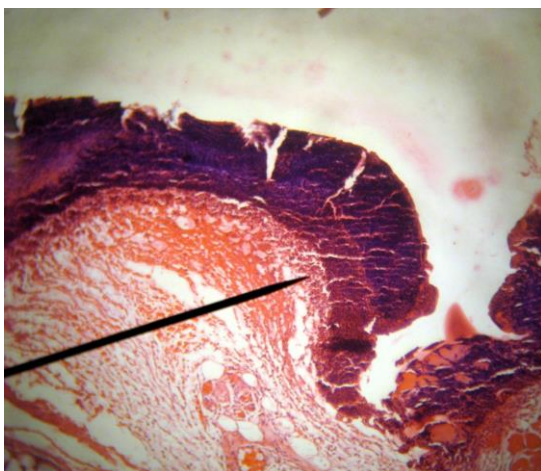
Groups	Time					
	Day 3	Day 5	Day 7	Day 14	Day 21	Day 28
Control (micron)	19050 ± 1159 <sup>a</sup>	18750 ± 1415 <sup>a</sup>	17900 ± 821.8 <sup>a</sup>	12350 ± 917.1 <sup>a</sup>	4800 ± 297.7 <sup>a</sup>	-
Experimental (micron)	18800 ± 1296 <sup>a</sup>	18200 ± 724.9 <sup>a</sup>	17450 ± 399.7 <sup>a</sup>	8700 ± 357.3 <sup>b</sup>	3300 ± 194.7 <sup>b</sup>	-

The different superscript letters mean significance level at  $p \leq 0.05$

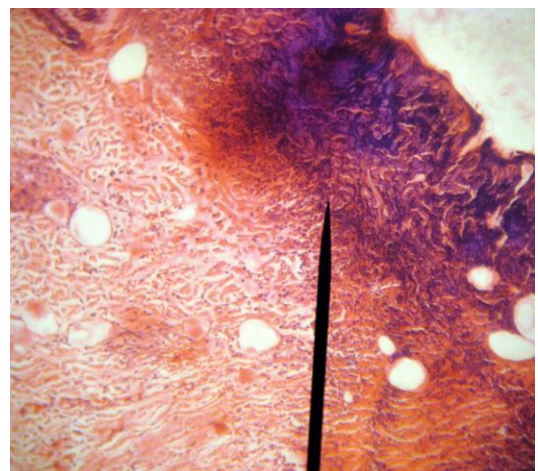
**Table 2.** Mean standard deviation of the inflammatory cell's infiltration in the skin of rabbits during three weeks of study

Groups	Time					
	Day 3	Day 5	Day 7	Day 14	Day 21	Day 28
Control (square micron)	195 ± 15.21 <sup>a</sup>	355 ± 25.14 <sup>a</sup>	301 ± 17.79 <sup>a</sup>	181 ± 10.32 <sup>a</sup>	25 ± 2.21 <sup>a</sup>	-
Experiment (square micron)	190 ± 12.02 <sup>a</sup>	280 ± 18.77 <sup>b</sup>	115 ± 5.12 <sup>b</sup>	25 ± 2.09 <sup>b</sup>	5 ± 0.61 <sup>b</sup>	-

The different superscript letters mean significance level at  $p \leq 0.05$

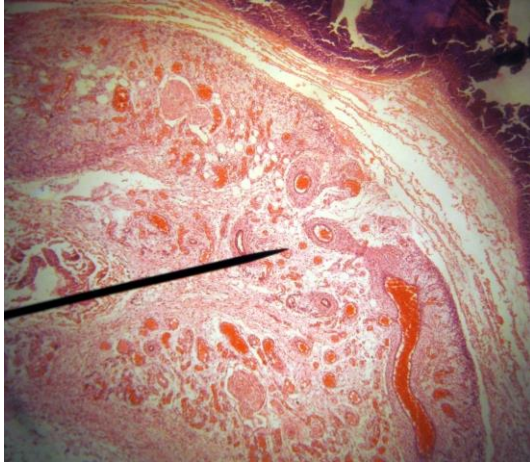


**Figure 1.** The view of wound site in a control rabbit on day three indicating aggregation of inflammatory cells between fibrin clot and necrotic tissue (Pointer). Blood vessels were seen under the wound area (H & E, ×100).

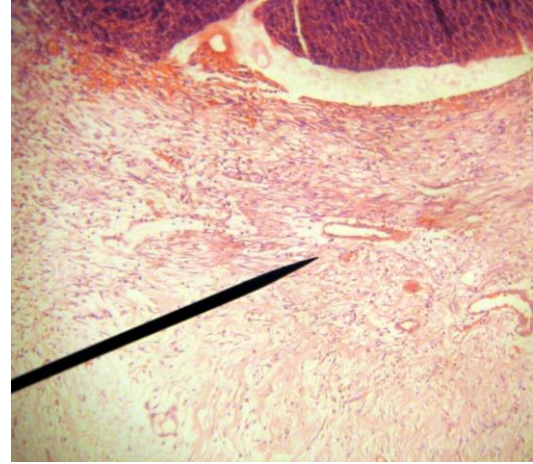


**Figure 2.** The view of wound site in a treatment rabbit on day three indicating a decrease in inflammatory cells in the wound area (Pointer). Blood vessels were seen in granulation tissue under the wound area (H & E, ×100).





**Figure 3.** The view of the wound site in a control rabbit on day five indicating severe angiogenesis with full-blood vessels (Pointer, H & E,  $\times 100$ ).



**Figure 4.** The view of wound site in a treated rabbit on day five indicating newly formed blood vessels (Pointer, H & E,  $\times 100$ ).

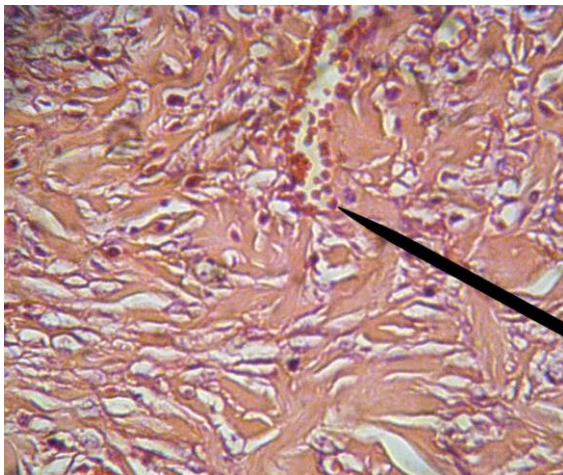
**Table 3.** Mean standard deviation of fibrin clot average diameter newly formed on skin wound of rabbits during four weeks of study

Groups	Time					
	Day 3	Day 5	Day 7	Day 14	Day 21	Day 28
Control (micron)	400 $\pm$ 29.49 <sup>a</sup>	850 $\pm$ 48.18 <sup>a</sup>	455 $\pm$ 34.58 <sup>a</sup>	450 $\pm$ 35.81 <sup>a</sup>	-	-
Experiment (micron)	350 $\pm$ 16.12 <sup>a</sup>	600 $\pm$ 39.70 <sup>b</sup>	250 $\pm$ 16.86 <sup>b</sup>	0 <sup>b</sup>	-	-

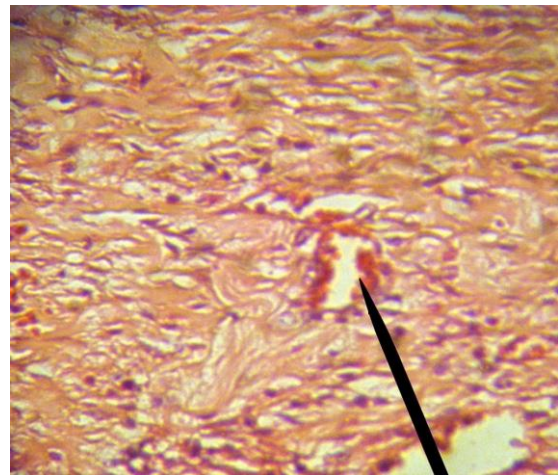
The different superscript letters mean significance level at  $p \leq 0.05$

day 5 ( $p \leq 0.05$ , Table 5). The comparison between granulation of samples is demonstrated in Figures 9-12. Finally, the epithelial tissue diameter was higher in the experiment group, compared to the control group on day 14, and remained that way until day 28. The difference was significant on days 14 and 21 (Table 6). According to the present literature, the effect of topical NTG has been efficient in wound healing<sup>8,9,19</sup>. In a recent study, Gündüz et al.<sup>20</sup> investigated the effects of NTG in the stasis zones of a burning model and reported significant differences in

edema, inflammation, and vascular proliferation in the NTG 2% group. Additionally, it was indicated NTG 2% could increase vascular proliferation in the zones of stasis and improve wound healing. In another study on rats, the effect of topical NTG together with Aloe vera was investigated on a rat model of diabetic foot. The results indicated that this combination could yield faster healing of the ulcer<sup>21</sup>. Moreover, another meta-analysis by Liu et al.<sup>22</sup> on 12 trials with 1095 patients of hemorrhoidectomy reported that using topical NTG had beneficial effects on pain relief



**Figure 5.** The view of wound site in a control rabbit on day seven showing a severe decline in cells and enhancement in volume and thickness of collagen (Pointer, H & E,  $\times 400$ ).



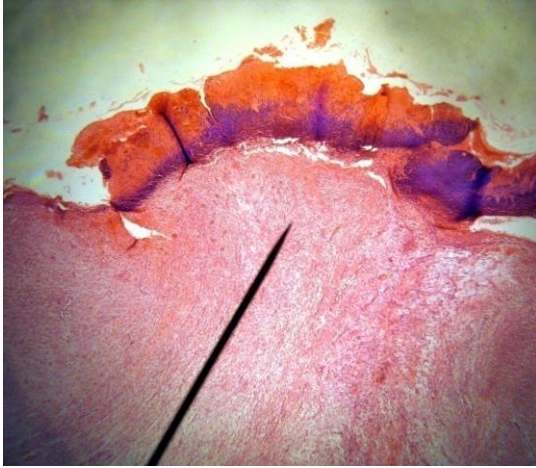
**Figure 6.** The view of wound site in a treated rabbit on day seven revealing more maturity, compared with the control group (Pointer). Collagen fibers are organized next to each other (H & E,  $\times 400$ ).

**Table 4.** Mean standard deviation of the number of blood vessels formed in the skin of rabbits during four weeks of study

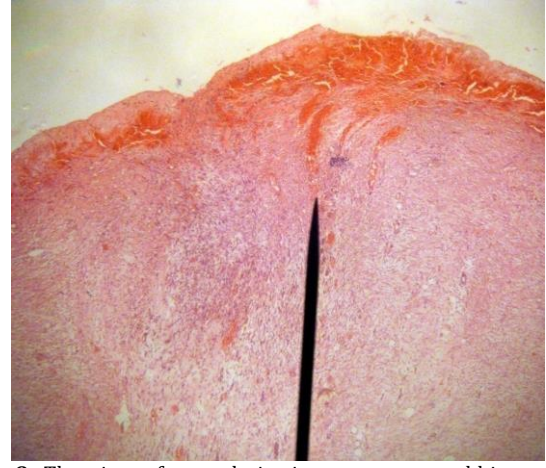
Groups	Time					
	Day 3	Day 5	Day 7	Day 14	Day 21	Day 28
Control (square millimeter)	120 $\pm$ 4.10 <sup>a</sup>	280 $\pm$ 10.57 <sup>a</sup>	165 $\pm$ 6.31 <sup>a</sup>	24 $\pm$ 1.73 <sup>a</sup>	0.01 <sup>a</sup>	0.01 <sup>a</sup>
Experiment (square millimeter)	40 $\pm$ 2.91 <sup>b</sup>	99 $\pm$ 4.98 <sup>b</sup>	160 $\pm$ 6.76 <sup>a</sup>	155 $\pm$ 8.27 <sup>b</sup>	25 $\pm$ 1.89 <sup>b</sup>	20 $\pm$ 1.07 <sup>b</sup>

The different superscript letters mean significance level at  $p \leq 0.05$





**Figure 7.** The view of the wound site in a control rabbit on day 14 demonstrating the growth of epithelium around the wound resulting in a fibrin clot and wound site limitation (Pointer). Granulation tissue can be seen under the wound site (H & E,  $\times 40$ ).



**Figure 8.** The view of wound site in a treatment rabbit on day 14 indicating the limitation of wound site as a result of epithelium growth and also severe bleeding and high-blood at the wound site (Pointer, H & E,  $\times 40$ )

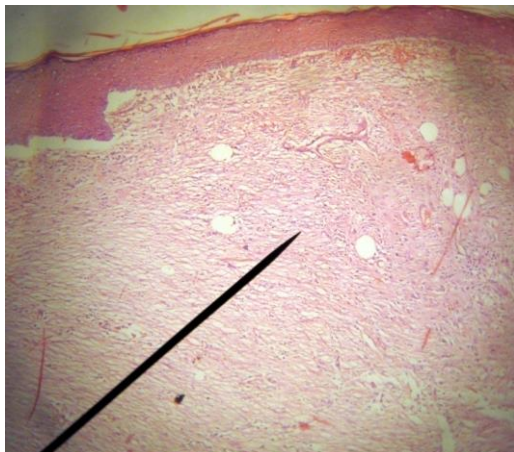
**Table 5.** Mean standard deviation of newly formed granulation in the skin of rabbits during three weeks of study

Groups	Time					
	Day 3	Day 5	Day 7	Day 14	Day 21	Day 28
Control (square micron)	6750 $\pm$ 224.13 <sup>a</sup>	3500 $\pm$ 99.23 <sup>a</sup>	1220 $\pm$ 60.26 <sup>a</sup>	900 $\pm$ 16.48 <sup>a</sup>	125 $\pm$ 2.99 <sup>a</sup>	0.01 <sup>a</sup>
Experiment (square micron)	7000 $\pm$ 38005 <sup>a</sup>	6600 $\pm$ 346.41 <sup>b</sup>	3750 $\pm$ 291.73 <sup>b</sup>	1250 $\pm$ 104.20 <sup>b</sup>	1200 $\pm$ 104.10 <sup>b</sup>	1000 $\pm$ 71.89 <sup>b</sup>

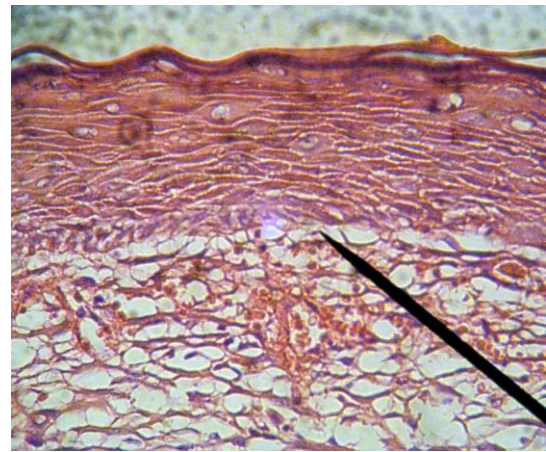
The different superscript letters mean significance level at  $p \leq 0.05$

and wound healing. This result together with the results of the meta-analysis by Ratnasingham et al.<sup>18</sup> provides strong evidence of NTG as a wound-healing agent. The topical NTG 2% was effective in the treatment of both the symptoms and lesion appearance of chondrodermatitis nodularis helices (CNH) in a non-invasive manner<sup>23</sup>. In a study by Wang et al.<sup>24</sup> on the efficacy and safety of topical NTG in the prevention of mastectomy flap necrosis, it was indicated

that NTG significantly reduced the risk of mastectomy flap necrosis, full-thickness flap necrosis, and debridement as well as the rate of early complications, compared to flap necrosis. In a systematic review and meta-analysis, the effect of topical GTN on tendinopathies was investigated and the findings revealed positive effects of GTN on short and intermediate treatments of tendinopathies and also significant influences on pain reduction<sup>25,26</sup>.



**Figure 9.** The view of the wound site in a control rabbit on day 21 showing a thin layer of epithelium on the wound site and granulation tissue under it (Pointer, H & E,  $\times 100$ )

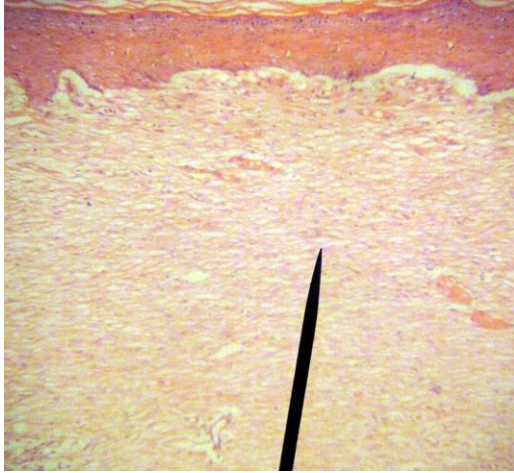


**Figure 10.** The view of wound site in a control rabbit on day 21 revealing newly formed epithelium (Pointer, H & E,  $\times 400$ )

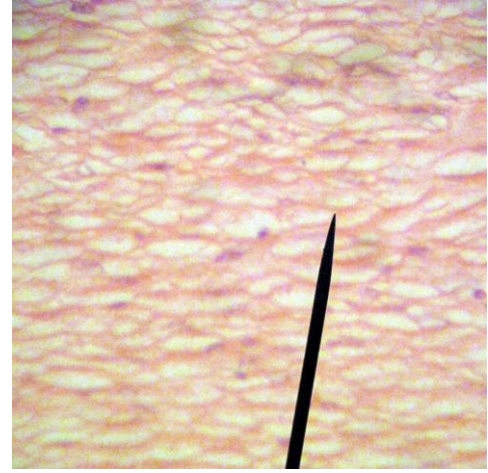
**Table 6.** Mean standard deviation of epithelial tissues' diameter per square millimeter in the skin of rabbits during four weeks of study

Groups	Time					
	Day 3	Day 5	Day 7	Day 14	Day 21	Day 28
Control (micron)	-	-	-	0.01 <sup>a</sup>	75 $\pm$ 4.47 <sup>a</sup>	150 $\pm$ 7.92 <sup>a</sup>
Experimental (micron)	-	-	-	5 $\pm$ 0.82 <sup>b</sup>	100 $\pm$ 6.99 <sup>b</sup>	178 $\pm$ 8.51 <sup>b</sup>

The different superscript letters mean significance level at  $p \leq 0.05$



**Figure 11.** The view of wound site in a treatment rabbit on day 21 demonstrating the higher growth of granulation tissue, compared to the control group (Pointer, H & E,  $\times 100$ )



**Figure 12.** The view of wound site in a treatment rabbit on day 21 indicating fully matured tissue granulation nearly without cells organized regularly next to each other (Pointer, H & E,  $\times 400$ )

## 4. Conclusion

The results of the present study revealed that NTG decreased wound edge's distance and the number of inflammatory cells (Neutrophils), and enhanced angiogenesis, newly formed granulation, and epithelial diameter in the treatment group. Thus, the topical usage of NTG 2% has a positive effect on wound healing. Overall, the present experiment suggests a promising function of topical NTG in wound healing of anal fissures, tendinopathies, CNH, diabetic foot, or skin flap necrosis. However, the obvious side effect of nitrates which is headaches and hypotension need to be kept in mind. Further clinical studies are required to assess the best formulation to have minimum side effects with the best wound healing effect.

## Declarations

### Acknowledgements

The current study was funded by the Faculty of Veterinary Medicine, Karaj Branch, Islamic Azad University, Karaj, Iran. The authors would like to express their appreciation to the Faculty of Veterinary Medicine, Karaj Branch, Islamic Azad University, Karaj, Iran for their collaboration, and support during all procedures of this experimental research.

### Competing interests

The authors declare that they have no competing interests.

### Authors' contribution

Arman Moshaveri designed the study and performed the sampling and practical procedures, Daryoush Babazadeh wrote the draft of the manuscript and check the final version of the article, Faezeh Modarresi-Ghazani revise the draft of the manuscript and remove the language

errors, Veghar Hejazi performed the statistical analysis, Muhammad Saeed and Pouria Ahmadi-Simab wrote the draft of the manuscript. All authors check the final proof of the article and the statistical results.

### Availability of data and materials

All data and related findings of the thesis are prepared for publishing in the present journal.

## References

- Brueckner CS, Becker MO, Kroencke T, Huscher D, Scherer HU, Worm M, Burmester G, and Riemekasten G. Effect of sildenafil on digital Ulcers in systemic sclerosis: analysis from a single centre pilot study. *Ann Rheum Dis*. 2010; 60: 1475-1478. DOI: <https://www.doi.org/10.1136/ard.2009.116475>
- Cross SE. An experimental model to investigate the dynamics of wound contraction. *Br J Plastic surgery*. 1995; 58: 189-197. DOI: [https://www.doi.org/10.1016/0007-1226\(95\)90001-2](https://www.doi.org/10.1016/0007-1226(95)90001-2)
- Salcido R. Wound Healing the NO Connection, advances in Skin and wound care. *J Prevention and Healing*. 2008; 21: 106-109. DOI: <https://www.doi.org/10.1097/01.ASW.0000305426.55671.42>
- Majure DT, Hallaux M, Yeghiazarians Y, and Boyle AJ. Topical nitroglycerin and lidocaine locally vasodilate the radial artery without affecting systemic blood pressure: a dose-finding phase I study. *J Crit Care*. 2012; 27: P532. DOI: <https://www.doi.org/10.1016/j.jccr.2012.04.019>
- Pipelzadeh M H, and et al. A study on the effect of modulation of intracellular calcium on excisional wound healing in rabbit. *Iranian Biomedical J*. 2003; 7: 161-166. Available at: <http://ibj.pasteur.ac.ir/article-1-523-en.pdf>
- Ignarro LJ, Cirino G, Casini A, and Napoli C. Nitric oxide as a signaling molecule in the vascular system: an overview. *J cardiovascular pharma*. 1999; 34: 879-886. DOI: <https://www.doi.org/10.1097/00005344-199912000-00016>
- Plumb Donald. *Plum's Veterinary Drug Handbook*, Sixth Edition, Blackwell. 2008; 658- 659. Available at: <https://www.amazon.com/Donald-C-Plumb-Pharm-D-Veterinary/dp/B005H7TYM6>
- Brisinda M, Maria G, Bentivoglio AR, Cassetta E, Gui D, and Albanese A. A Comparison of Injections of Botulinum Toxin and Topical Nitroglycerin Ointment for the Treatment of Chronic Anal Fissure. *N Engl J Med*. 1999; 341: 65-69. DOI: <https://www.doi.org/10.1056/NEJM199907083410201>
- Sanei B, Mahmoodieh M, and Masoudpour H. Comparison of topical glyceryl trinitrate with diltiazem ointment for the treatment of chronic anal fissure: a randomized clinical trial. *Acta Chir Belg*. 2009; 109: 727-730. DOI: <https://www.doi.org/10.1080/00015458.2009.11680524>
- Ahmadijedad M, Khaksarhaddad M, Amirhasani A, Khazaeli P,



- AsadiShekari M, Ahmadipour M, and TahmasebyS. Compression of Efficacy of Topical Phenytoin, Honey and Combination of Honey with Triglyceride Tree Nitrate on Wound Healing in Rat. *Indian J Forensic Med and Toxicology*. 2019; 13: 393-398. DOI: <https://www.doi.org/10.5958/0973-9130.2019.00320.7>
11. Heggers JP, Elzaim H, Garfield R, Goodheart R, Listengarten D, Zhao J, and Phillips LG. Effect of the combination of Aloe vera, nitroglycerin, and L-NAME on wound healing in the rat excisional model. *J Altern Complement Med*. 1997; 3: 149-153. DOI: <https://www.doi.org/10.1089/acm.1997.3.149>
12. Ellabban MA, Fattah IOA, Kader GA and et al. The Effects of Sildenafil and/or Nitroglycerin on Random pattern Skin Flaps After Nicotine Application in Rats. 2020; 10: 3212. DOI: <https://www.doi.org/10.1038/s41598-020-60128-w>
13. Dunn CL, Brodland DG and et al. A single postoperative application of nitroglycerin ointment does not increase survival of cutaneous flaps and grafts. *Dermatol surg*. 2000; 26: 425-427. DOI: <https://www.doi.org/10.1046/j.1524-4725.2000.99307.x>
14. Cihan AO, Bicakci U, Tander B, Rizalar R, Kandemir B, Ariturk E, and Bernay F. Effects of intra peritoneal nitroglycerin on the strength and healing attitude of anastomosis of rat intestines with ischemia-reperfusion injury. *Afr J Paediatr Surg*. 2011; 8: 206-210. DOI: <https://www.doi.org/10.4103/0189-6725.86064>
15. Hwang DY, Yoon SG, Kim HS, Lee JK, and Kim KY. Effect of 0.2 percent glyceryl trinitrate ointment on wound healing after a hemorrhoidectomy: Results of a randomized, prospective, double-blind, placebo-controlled trial. *Dis Colon Rectum*. 2003; 46: 950-954. DOI: <https://www.doi.org/10.1007/s10350-004-6692-0>
16. Kim SW, Kim H, and Hyun M. Nitroglycerin Ointment Enhances the Wound Healing Effect of Adipose-Derived Stem Cells. *Int J Stem Cells Res*. 2020; 4: 1-5. DOI: <https://www.doi.org/10.1155/2019/2745640>
17. Karanik H, Akturk R, Camlica H, and Asoqlu O. The effect of glyceryl trinitrate ointment on post hemorrhoidectomy pain and wound healing: Results of a randomized, double-blind, placebo-controlled study. *Dis Colon Rectum*. 2009; 52: 280-285. DOI: <https://www.doi.org/10.1007/DCR.0b013e31819c98a7>
18. Ratnasingham K, Uzzaman M, Andreani SM, Light D, and Patel B. Meta-analysis of the use of glyceryl trinitrate ointment after haemorrhoidectomy as an analgesic and in promoting wound healing. *Int J Surg*. 2010; 8: 606-611. DOI: <https://www.doi.org/10.1016/j.jisu.2010.04.012>
19. Cihan AO, Bicakci U, Tander B, Rizalar R, Kandemir B, Ariturk E, and Bernay F. Effects of intra peritoneal nitroglycerin on the strength and healing attitude of anastomosis of rat intestines with ischemia-reperfusion injury. *Afr J Paediatr Surg*. 2011; 8: 206-210. DOI: <https://www.doi.org/10.4103/0189-6725.86064>
20. Gündüz M, Sekmenli T, Uğurluoğlu C, and Çiftçi İ. The effects of nitroglycerin in the zone of stasis in a rat burn model. *Ulus Travma Acil Cerrahi Derg*. 2020; 26: 171-177. DOI: <https://www.doi.org/10.14744/tjtes.2019.00005>
21. Hotkar MS, Avachat AM, Bhosale SS, Oswal YM. Preliminary investigation of topical nitroglycerin formulations containing natural wound healing agent in diabetes-induced foot ulcer. *International wound J*. 2015; 12: 210-217. DOI: <https://www.doi.org/10.1111/iwj.12084>
22. Liu JW, Lin CC, Kiu KT, Wang CY, and Tam KW. Effect of glyceryl trinitrate ointment on pain control after hemorrhoidectomy: a meta-analysis of randomized controlled trials. *World J surgery*. 2016 ; 40: 215-224. DOI: <https://www.doi.org/10.1007/s00268-015-3344-6>
23. Flynn V, Chisholm C, and Grimwood R. Topical nitroglycerin: a promising treatment option for chondro dermatitis nodularis helices. *J Acad Dermatol*. 2011; 65: 531-536. DOI: <https://www.doi.org/10.1016/j.jaad.2010.06.012>
24. Wang P, Gu L, Qin Z, and et al. Efficacy and safety of topical nitroglycerin in the prevention of mastectomy flap necrosis: a systematic review and meta-analysis. 2020; 10: 6753. DOI: <https://www.doi.org/10.1038/s41598-020-63721-1>
25. Challoumas D, Kirwan PD, Borysov D, and et al. Topical glyceryl trinitrate for the treatment of tendinopathies: a systematic review *British J Sports Med*. 2019; 53: 251-262. DOI: <https://www.doi.org/10.1136/bjsports-2018-099552>
26. Gambito ED, Gonzalez-Suarez CB, Oquifena TI, and Agbayani RB. Evidence on the effectiveness of topical nitroglycerin in the treatment of tendinopathies: a systematic review and meta-analysis. *Arch Phys Med Rehabil*. 2010; 91: 1291-1305. DOI: <https://www.doi.org/10.1016/j.apmr.2010.02.008>